

**A Case of Intussuscepted Meckle's Diverticulum
Diagnosed through Computed Tomography Scan of the
Abdomen**

A Case of Intussuscepted Meckle's Diverticulum Diagnosed Through Computed Tomography Scan of the Abdomen

Khaled Moghazy*, Hind El-Seif **, Yasser Al-Jehani***, Khairi Hassan****

** Department of Radiology, ** Department of Radiology, *** Department of Surgery, College of Medicine, King Faisal University, Dammam, **** King Fahd Hospital of the University, Al Khobar, Saudi Arabia*

Abstract

Meckle's diverticulum, the commonest congenital anomaly of the gastrointestinal tract, can become the leading point of intestinal intussusception. However, the precise pre-operative diagnosis can be difficult. We report here a case of a 15-year old boy with acute abdomen in whom intussuscepted Meckle's diverticulum was diagnosed pre-operatively by CT scan. We conclude that CT scan is a safe, non-invasive tool to diagnose this condition before surgery and can improve outcome, especially in the acute abdomen with doubtful diagnosis.

Keywords: Meckle's diverticulum, intussusception, Computed Tomography

Correspondence

Dr. Khaled M. Moghazy

P.O. Box 40076

Al-Khobar 31952

Kingdom of Saudi Arabia

Email: moghazykhaled@yahoo.com

Introduction

Meckel's diverticulum (MD) is the commonest congenital anomaly of the gastrointestinal tract, occurring in 2%-3% of the population (1). It is usually found within 100 cm of the ileocecal valve on the antimesenteric border of the distal ileum (1, 2). It may become the leading point of intestinal intussusception (4-5). Despite the availability and wide use of modern imaging techniques, the precise preoperative diagnosis of this complication is still difficult (4-6). There are few reports on CT demonstration of inverted Meckel diverticulum causing intussusception. The aim of this report is to demonstrate the role of CT in diagnosing intussuscepted Meckel's diverticulum.

Scenario

A 15-year old boy presented to the emergency room with abdominal pain of 2 days duration with fever, anorexia and lethargy. The pain was localized in the umbilical region, severe, intermittent and with no radiation. It was increased by eating and decreased by anti-spasmodic drugs. It was associated with nausea, vomiting of food content, constipation and abdominal distention. He had mild abdominal tenderness but no rebound tenderness. Bowel sounds were exaggerated. Standing X-ray of abdomen showed dilated loops of small bowel with multiple air-fluid levels diagnostic of acute small intestinal obstruction. Computed Tomography (CT) of the abdomen with IV contrast confirmed dilated small bowel loops with collapsed colon and mild ascites. The impression was sub-acute intestinal obstruction secondary to intussusception (Fig. 1A, 1B). After IV fluids, antispasmodics and antibiotics, diagnostic laparoscopy showed bile-stained peritoneal fluid, distended small bowel loops with collapsed terminal ileum. Laparotomy showed ileoileal intussusception which was reduced manually. An inflamed MD was found, 40 cm from the ileocecal valve, as the leading point of intussusception. Wedge resection with primary ileoileal anastomosis was done. Pathological diagnosis was inverted MD with severe inflammation. The patient's post-operative course was uneventful

and he was improved and discharged home after four days later.

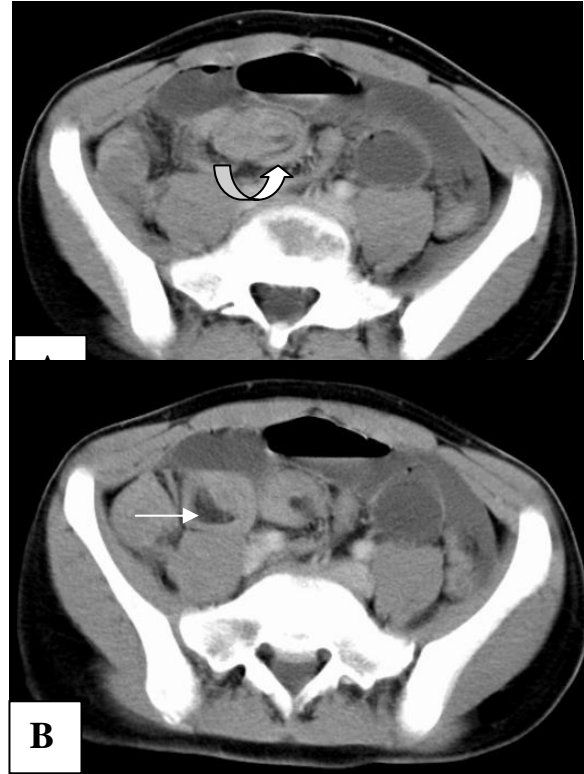


Figure (1). (A & B) CT scan of the lower abdomen showing two small bowel loops in the region of the terminal ileum that showed multiple concentric rings of tissue (curved arrow), and intra-luminal mass with fatty component (arrow) representing ileoileal intussusception.

Discussion

Meckel Diverticulum (MD) is mostly asymptomatic. However, 17% to 22% have variable clinical symptoms due to complications such as hemorrhage (1) and intestinal obstruction (1, 2). MD can produce obstruction in 5 ways: inversion causing luminal obstruction, leading point in an intussusception, volvulus from persistent attachment to the umbilicus, adhesions or as foreign body impaction. Intussusception secondary to MD was reported to be about 2.5-5% of cases of mechanical small bowel obstruction (1,7). The mesenteric fat of

the MD becomes pulled into the center of the diverticulum as it invaginates into the small intestinal lumen. Once inverted, the diverticulum can serve as the site of intestinal obstruction or leading point for an ileoileal or ileocolic intussusception (1).

CT characteristically shows the inverted diverticulum as a central core of fat attenuation surrounded by a collar of multiple concentric rings of soft-tissue attenuation (Fig. 1A, 1B). The differential diagnosis for an inverted MD on CT scan is lipoma. However, in intestinal lipomas, the fat attenuation seen on CT scan lacks the associated collar of soft-tissue attenuation that is seen in inverted MD (1). Furthermore, the capsular structure is much thinner instead of the entire intestinal wall as seen in our case. In reported cases (8, 9) it was shown that the outer aspect of inverted MD was covered with mucosa and its core consisted of fat tissue, the same pathological findings as in our case. We conclude that CT was useful in the preoperative diagnosis of intussuscepted Meckle's diverticulum.

References

1. Levy A D and Hobbs CM. From the Archives of the AFIP: Meckel Diverticulum: Radiologic Features with Pathologic Correlation. *Radiographics* 2004;24:565-587.
2. Fa-Si-Oen PR, Roumen RM, Croiset van Uchelen FA. Complications and management of Meckel's Diverticulum: a review. *Eur J Surg* 1999; 165:674-678
3. Pantongrag-Brown L, Levine MS, Elsayed AM, Buetow PC, Agrons GA, Buck JL. Inverted Meckel diverticulum: clinical, radiologic, and pathologic findings. *Radiology* 1996; 199:693-696
4. Rossi P, Gourtsoyiannis N, Bezzi M, Raptopoulos V, Massa R, Capanna G, Pedicini V, and Coe M. Meckel's diverticulum: imaging diagnosis. *AJR* 1996; 166: 567 - 573
5. Chew FS, Zamuto DA. Meckel's diverticulum. *AJR* 1992; 159:982
6. Nigogsyan M, Dolinskas C. Case report. CT demonstration of inflamed Meckel's Diverticulum. *J Comput Assist Tomogr* 1990; 14:140-142
7. Hamada T, Ishida O, Yasutomi M. Inverted Meckel diverticulum with intussusception: Demonstration by CT. *Journal of computed assisted tomography* 1996; 20:287-289.
8. Kiproff DD, Griffel B. Inversion of Meckel diverticulum *Arch Surg* 1975;110:1154.
9. Nagi B, Kochhar R, Malik AK. Inverted Meckel diverticulum shown by enteroclysis. *AJR* 1991; 156:1111-1112