

**Orthodontic Management of Pathological Migration of
Central Incisor in a Patient with Moderate to Severe
Periodontal Disease**

Orthodontic Management of Pathological Migration of Central Incisor in a Patient with Moderate to Severe Periodontal Disease

Mohammad A. Al-Mohaimed

Abstract

Proclination and extrusion of upper central incisors are considered as the main manifestations of pathological migration. They are the most common chief complaint of adult patients nowadays. With adequate orthodontic-periodontal teamwork it is possible to reestablish a healthy and well-functioning dentition with good occlusion, sufficient masticatory function, and satisfactory esthetics that will improve the psychological status of the patient after correcting the elongation and the migration of the anterior teeth. This report presents a case with pathological migration of upper right central incisor treated orthodontically with a combination of intrusion, extrusion and retraction movement. This mechanics improve the bone topography, improve esthetics and also helps the patient to achieve good home oral hygiene care.

Key words: pathological migration, orthodontic intrusion, orthodontic extrusion, adult orthodontic

Correspondence:

*Dr. Mohammad A. Al-Mohaimed
Asstt. Professor, Preventive Department*

*College of Dentistry, Qassim University
P.O.Box: 6040 Airport mail 51433
Saudi Arabia.
e-mail, malmohaimed@gmail.com*

During the last decade the number of adults seeking orthodontic treatment has increased significantly. Nowadays in the United States more than 20% of orthodontic patients are adults and that number will no doubt increase as the median age of our population increases.⁽¹⁾

However, more than half of all people over age 18 year have at least an early stage of periodontal disease. After age 35 year, about three out of four adults are affected to some degree with periodontal disease.⁽²⁾

The classic periodontal patient usually presents with the maxillary labial segment showing proclination, spacing, rotations, and overeruption of the dentition.⁽³⁾ However, these changes decrease the ease of plaque control, compromise the aesthetic and also the function.⁽³⁾

Pathological migration is defined as a change in tooth position resulting from disruption of the forces that maintain the teeth in a normal position, with reference to the skull.⁽⁴⁾ Others defined it as the presence of a developing diastema in the upper anterior sextant, which was not present in the past or already existed but increased.⁽⁵⁾ The prevalence of pathological migration has been reported as 30%⁶ to 55%⁽⁶⁾.

The degree of migration will differ from tooth to tooth, according to the periodontal destruction and the forces acting on the single tooth.⁽⁷⁾

Periodontal disease destruction of the attachment apparatus plays a major role in the etiology of pathological migration producing esthetic and functional problems for the patient.⁸

The negative effects of the orthodontic treatment on periodontal tissues have been investigated in several studies. Loss of periodontal bone support may occur during orthodontic realignment of pathologically migrated front teeth.⁽⁸⁾ However, with proper treatment and good oral hygiene maintenance no further periodontal tissue breakdown will occur.⁽⁹⁾ The new periodontal architecture following teeth realignment helps patients to achieve good home oral hygiene care.⁽¹⁰⁾

It has been reported that intrusive movement has been recommended in cases of pathologic migration, to realign the teeth and improve clinical crown length and marginal bone levels.⁽¹¹⁾

Histological studies suggest that new cementum and collagen attachment was formed after orthodontic intrusion if good oral hygiene was maintained.^(12,13)

With adequate orthodontic-periodontal teamwork it is possible to reestablish a healthy and well-functioning dentition with good occlusion, sufficient masticatory function, and satisfactory esthetics that will improve the psychological status of the patient after correcting the elongation and the migration of the anterior teeth.⁽¹⁰⁾

Diagnosis

A 36-year-old female attended the orthodontic clinic with a chief complaint of "My front tooth changed its position and moved since one year" (Figure). She has a history of periodontal disease. She received periodontal treatment, deep scaling and root planning, followed by regular periodontal maintenance. Upon examination, she has a generalized gingivitis with marked severe bone loss in the upper and lower anterior region especially teeth # 11, 42 and mesial to # 35 (Figure ,3).

Treatment Objectives

The treatment objectives were to improve (1) patient esthetics and help her to maintain a healthy periodontium, and (2) the bone level of the affected tooth by over-intrusion and then controlled teeth leveling.

Treatment Plan

The treatment plan includes: (1) maintenance of periodontal health by home care; (2) regular visits with the periodontist at fixed intervals during active orthodontic treatment. (3) intrusion and retraction of the extruded incisor # 11, with torque control; (4) reinforce the anchorage with transpalatal arch; (5) close lower spaces by retraction of lower incisors; (6) finishing and detailing; and finally (7) retention with maxillary and mandibular 3-3 fixed bonded retainers.

Treatment Mechanics and Progress

The transpalatal arch was cemented to the 1st molars. A full .022" slot preadjusted edgewise appliance was bonded to the mandibular arch and upper right central incisor only (Figure). An .0175" Multistrand archwire was inserted in the lower arch for alignment, and an .016"x.022" TMA intrusion archwire in the upper arch with palatal root torque to increase the thickness of the labial bone, and closing loop activated slightly to counter-act the proclination effect of intrusion and torquing.

When over-intrusion of the upper right maxillary incisor was achieved (Figure 5), a full .022" preadjusted edgewise appliance was bonded to the maxillary arch for leveling and alignment.

The mandibular wire was progressively increased up-to .016"x.022" SS arch wire, and then the spaces were closed by power chain.

After one year and 7 weeks of treatment (Figure 6), a multistranded wire was bonded lingually in the upper and lower anterior from canine to canine as a retainer.

Results

The good buccal occlusion was preserved; the midline was corrected and coincided with the facial midline. The spaces were closed and proper incisor relationship and lip competency was achieved. Intrusion of the right maxillary central incisor was evident both clinically and radiographically (Figure 6,7&9), and accordingly the periodontal condition was improved.

The relationship between the root length before (R1) and after (R2) treatment was calculated according to the following formula:

$$\text{Rate of resorption} = \frac{C_2 - R_2}{C_1 - R_1}$$

The shortening of the maxillary incisor was 19%; which within acceptable range.

Discussion

Venrooy and Yukna⁽¹⁴⁾ recommended forced eruption as a method for treatment of an osseous defect caused by periodontal disease to level the bone margin and eliminate the diseased pockets. However, occlusal reduction that is a necessary consequence of the lengthening of the crown and often leads to the need for prosthetic and endodontic treatment.

As the intrusion is recommended in cases with pathological migration, when relating the change in the distance between the marginal gingiva and the cemento-enamel junction to the amount of intrusion and the change in marginal bone level, it could be anticipated that major infrabony pockets had developed during treatment.⁽¹¹⁾ Extrusion has been advocated as the method of choice in cases of vertical bone loss because apposition associated with extrusion can help to fill in vertical bone loss by apposition and result in a leveling of the alveolar bone.⁽¹⁴⁾

In the present case, both mechanics are applied, started with intrusion to improve the alignment of the tooth and over-intrusion to give a chance for extrusion in order to avoid crown reduction and endodontic treatment, and improve the osseous topography.

Orthodontic force should be kept within biological limits, which is minimized when applied to teeth with compromised bone support, because of the diminished PDL area.

The best results are obtained with light forces (5 to 15 g/tooth) and the line of action of the force passes close to the center of resistance.⁽¹¹⁾

The interval of orthodontic force activation should also be longer, because remodeling the periodontal tissues will take longer than in patients with healthy periodontal tissues.^(1,8)

Several authors have investigated the correlation between the amount of intrusion and the amount of root resorption. Dermaut and Demunck¹⁵, McFadden et al⁽¹⁶⁾ reported a low correlation. Others have reported that root resorption would increase with intrusion of incisors.^(17,18) In the present case; the root resorption of the maxillary right central incisor which is the highest is 19%. This is relatively similar with the finding of Dermaut and Demunck¹⁵ who reported 18% maxillary root shortening and slightly higher than McFadden et al¹⁶ who found a 1.84 mm or 13.2%. The periodontal status of the present case was maintained by regular control and by the meticulous hygiene, thus providing satisfactory result.

Since it is mentioned in the literature that the dentition with severe bone loss show a high tendency for relapse after active orthodontic treatment,⁽¹⁹⁾ therefore a fixed 3-3 retainers were bonded in the upper and lower jaws.

Acknowledgement

I would like to thank Professor Hayder A. Hashim for his supervision during the treatment of this case and also for revising this manuscript.

References

1. Boyd RL, Leggott PJ, Quinn RS, Eakle WS, Chambers D. Periodontal implications of orthodontic treatment in adults with reduced or normal periodontal tissues versus those of adolescents. *Am J Orthod Dentofacial Orthop* 1989;96:191-198.
2. Turpin DL. Periodontal screening: a basic part of the orthodontic examination. *Angle Orthod* 1994;64:163-164.
3. Ong MM, Wang HL. Periodontic and orthodontic treatment in adults. *Am J Orthod Dentofacial Orthop* 2002;122:420-428.
4. Chasens A. Periodontal disease, pathologic tooth migration and adult orthodontics. *N Y J Dent* 1979;49:40-43.
5. Martinez-Canut P, Carrasquer A, Magan R, Lorca A. A study on factors associated with pathologic tooth migration. *J Clin Periodontol* 1997;24:492-497.
6. Towfighi PP, Brunsvold MA, Storey AT, Arnold RM, Willman DE, McMahan CA. Pathologic migration of anterior teeth in patients with moderate to severe periodontitis. *J Periodontol* 1997;68:967-972.
7. Melsen B, Agerbaek N. Orthodontics as an adjunct to rehabilitation. *Periodontol* 2000 1994;4:148-159.
8. Artun J, Urbye KS. The effect of orthodontic treatment on periodontal bone support in patients with advanced loss of marginal periodontium. *Am J Orthod Dentofacial Orthop* 1988;93:143-148.
9. Eliasson LA, Hugoson A, Kurol J, Siwe H. The effects of orthodontic treatment on periodontal tissues in patients with reduced periodontal support. *Eur J Orthod* 1982;4:1
10. Re S, Corrente G, Abundo R, Cardaropoli D. Orthodontic Treatment in Periodontally Compromised Patients: 12-Year Report. *Int J Periodontics Restorative Dent* 2000;20:31-39.
11. Melsen B, Agerbaek N, Markenstam G. Intrusion of incisors in adult patients with marginal bone loss. *Am J Orthod Dentofacial Orthop* 1989;96:232-241.
12. Melsen B. Tissue reaction following application of extrusive and intrusive forces to teeth in adult monkeys. *Am J Orthod* 1986;89:469-475.
13. Melsen B, Agerbaek N, Eriksen J, Terp S. New attachment through periodontal treatment and orthodontic intrusion. *Am J Orthod Dentofacial Orthop* 1988;94:104-116.
14. van Venrooy JR, Yukna RA. Orthodontic extrusion of single-rooted teeth affected with advanced periodontal disease. *Am J Orthod* 1985;87:67-74.
15. Dermaut LR, De Munck A. Apical root resorption of upper incisors caused by intrusive tooth movement: a radiographic study. *Am J Orthod Dentofacial Orthop* 1986;90:321-326.
16. McFadden WM, Engstrom C, Engstrom H, Anholm JM. A study of the relationship between incisor intrusion and root shortening. *Am J Orthod Dentofacial Orthop* 1989;96:390-396.
17. Harry MR, Sims MR. Root resorption in bicuspid intrusion. A scanning electron microscope study. *Angle Orthod* 1982;52:235-258.
18. Otto RL, Anholm JM, Engel GA. A comparative analysis of intrusion of incisor teeth achieved in adults and children according to facial type. *Am J Orthod* 1980;77:437-446.
19. Ericsson I, Thilander B. Orthodontic relapse in dentitions with reduced periodontal support: an experimental study in dogs. *Eur J Orthod* 1980;2:51-57.

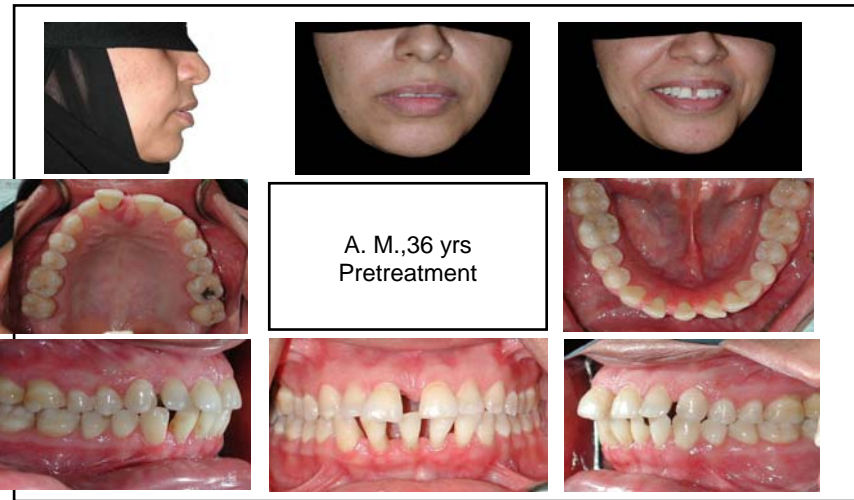

Figure 1. Pretreatment intraoral photograph

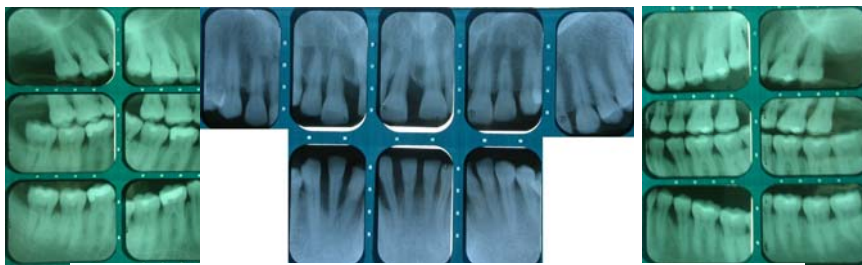


Figure 2. Pretreatment intraoral radiograph

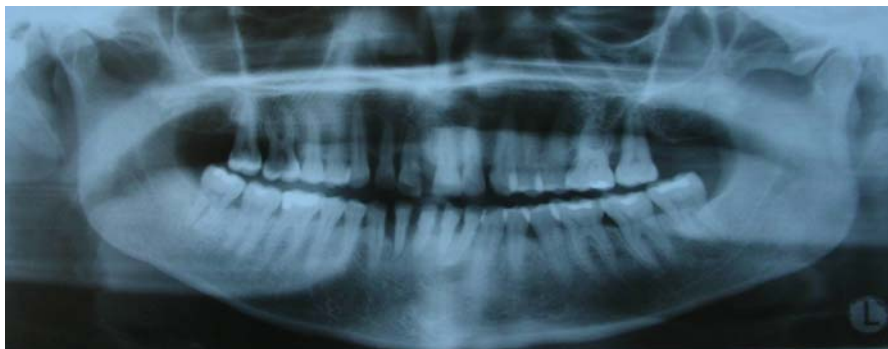

Figure 3. Pretreatment orthopantomograph

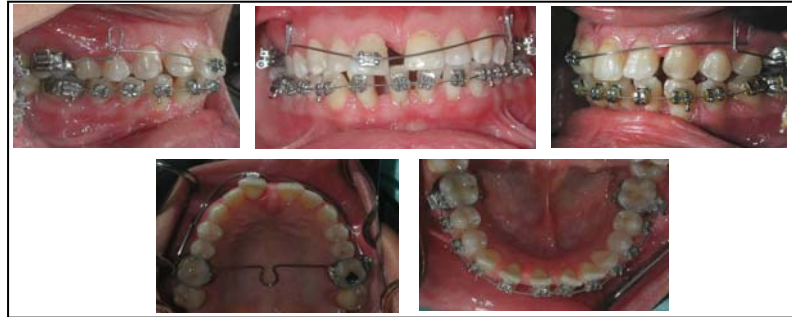

Figure 4. Day of bonding.

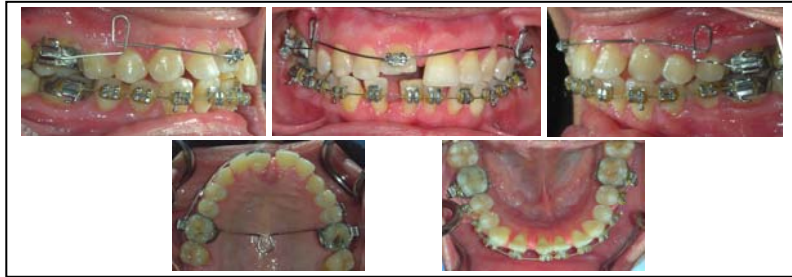

Figure 5. Over intrusion of upper right central incisor.

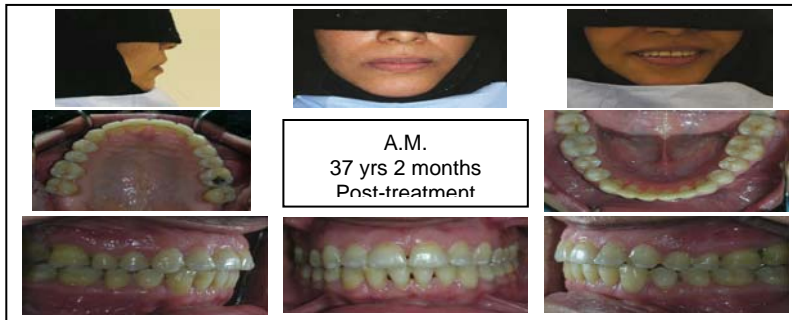

Figure 6 Post-treatment photograph

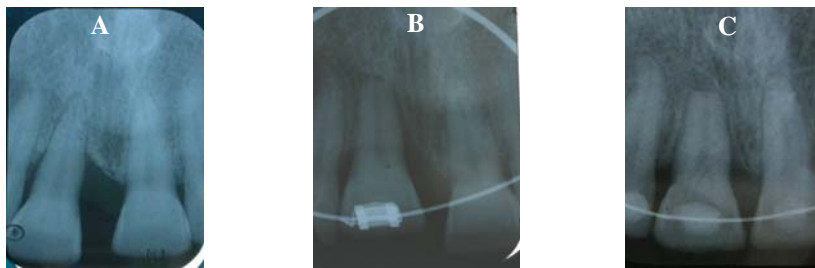

Figure 8. Periapical radiograph: (A) Before treatment (B) After intrusion (C)

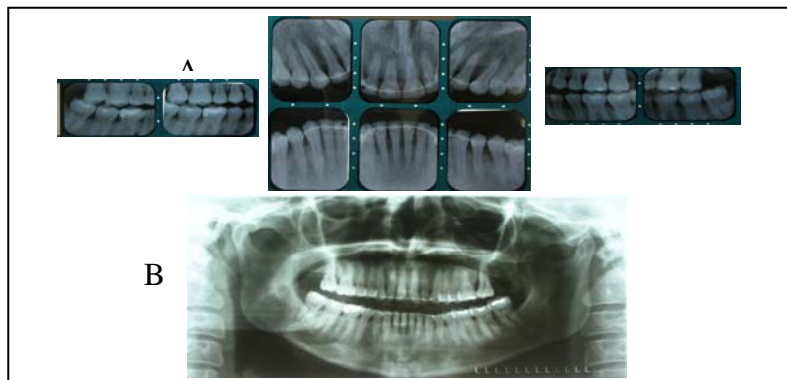


Figure 7. Post-treatment radiograph: (A) Periapical (B) Orthopantomograph.

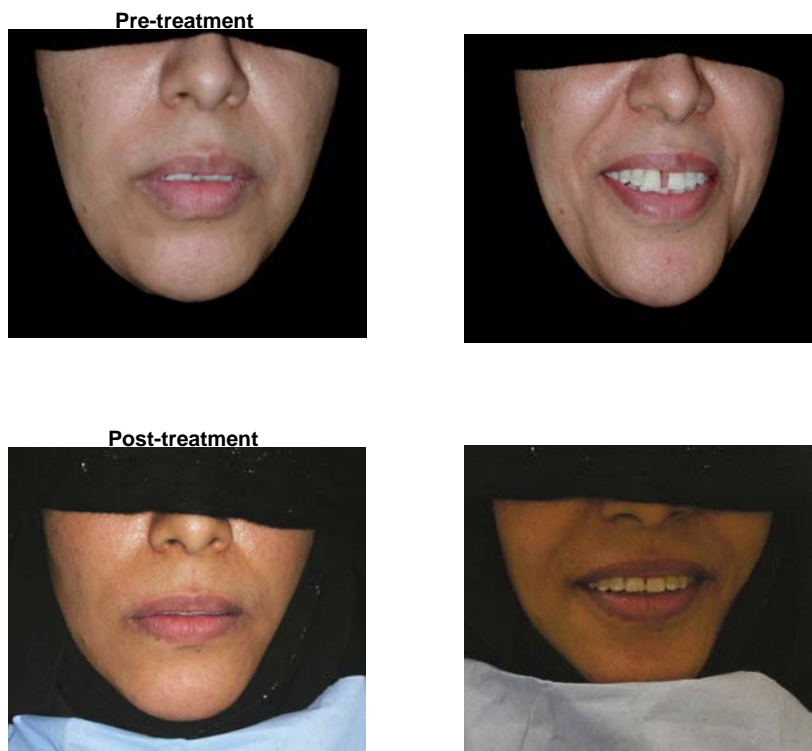


Fig 9. Pre-treatment and Post-treatment