

Intra-parenchyma Pneumocephalus: a Complication of Cochlear Implant

Intra-parenchyma Pneumocephalus: a Complication of Cochlear Implant

Abdulrahman Hagr and Manohar Bance***

**King Saud University/King Abdulaziz University Hospital Riyadh, Saudi Arabia.*

***Division of Otolaryngology, (Department of Surgery), Dalhousie University, Halifax, Nova Scotia, Canada.*

Abstract

Objective: We report an extremely rare case of pneumocephalus after cochlear implantation.

Method: Case report and a review of the world literature on pneumocephalus after cochlear implantation.

Results: We present a case of uneventful cochlear implantation in a patient with nasal polyposis. Post-operative nose blowing resulted in subcutaneous emphysema pneumocephale presenting five weeks post surgery. This resolved on conservative therapy, and the patient went on to use her implant successfully.

Conclusion: To our knowledge this is the first report in the world literature of delayed onset as well as asymptomatic pneumocephalus after cochlear implantation

Key words: Cochlear implant and pneumocephalus

Correspondence:

Abdulrahman Hagr

Department of Otolaryngology

King Abdulaziz University Hospital

P .O .Box 245 Riyadh 11411

Saudi Arabia.

Case Report

48 year old woman had left cochlear implantation (Clarion 90 K) for bilateral profound deafness since the age of 5 years. She had uneventful course post-operatively and cochlear implant was activated four weeks after surgery. HINT scores was 0% and 22% pre-operatively and 1.5 months post-operatively respectively. She had a history of nasal polyposis in the past with multiples surgeries for this, and was a frequent nose blower.

Five weeks after surgery she presented with a 3 day history of fever of 103 °F, earache and swelling around her left ear. There was no history of severe headache, anorexia, nausea and vomiting, dehydration, seizures or photophobia. On examination she did not have any sign of meningitis or increased intracranial pressure. The left ear tympanic membrane looked red and bulging. She had fluctuant subcutaneous swelling around the Cochlear Implant. This was aspirated under aseptic conditions, but only air was aspirated, with no fluid. She was admitted on intravenous ceftriaxone and CT scanning performed. The CT scan (Figures 1 and 2) shows air subcutaneously tracking along the electrode exit array from the mastoid cavity. Intracranial air was also seen.

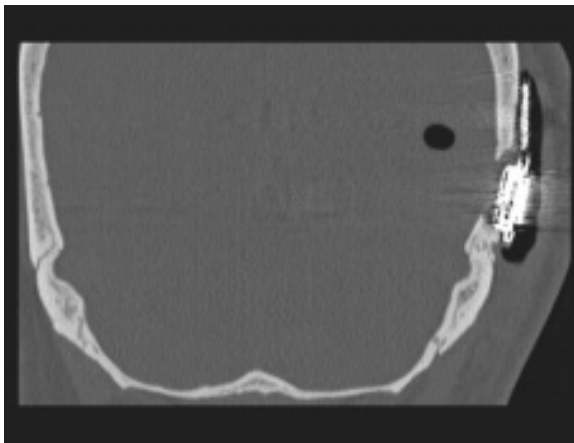


Figure (1). High-resolution CT scan coronal cut showing the cochlear implant, extracranial soft tissue free air as well as intra-parenchymal pneumocephalus.

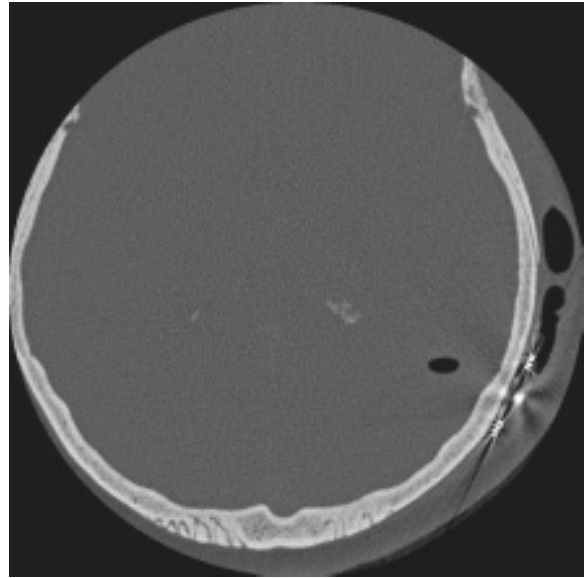


Figure (2). High-resolution CT scan axial cut showing the extracranial soft tissue free air as well as intra-parenchymal pneumocephalus.

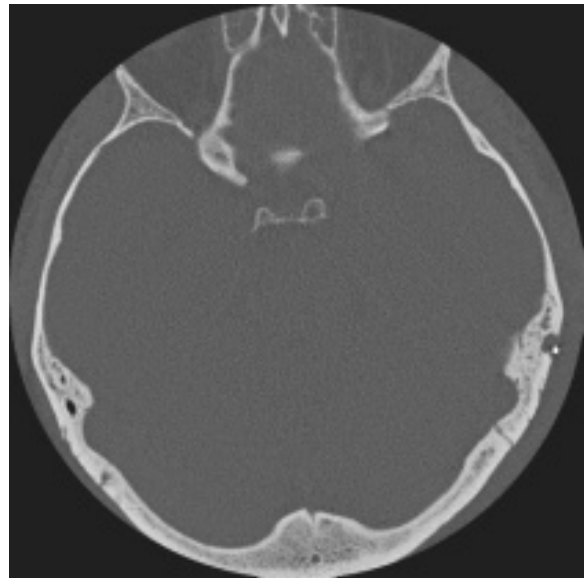


Figure (3). High-resolution CT scan 2 days later. Pneumocephalus is no longer present.

The patient had difficulty with complying with avoidance of nose blowing, and so a pressure equalization tube was inserted to decompress the middle ear pressure and prevent further insufflations of air. Neurosurgery consultation advised using high inspired oxygen concentration (100%) to facilitate absorption of the intracranial air collection. Follow-up CT scan 2 days later showed complete resolution of the

pneumocephalus (Fig 3). Patient was discharged home on oral antibiotic and oral steroids to shrink her nasal polyps, for polyp surgery with her referring Otolaryngologist. Three months later, CT scan was repeated and showed normal brain with no pneumocephalus. She continues to use the implant without complications, and has had no recurrence of air or infection.

Discussion

Pneumocephalus (the accumulation of intracranial air) is usually associated with craniofacial surgery, trauma, infection, or neoplasm. Regardless of the causes, pneumocephalus could have high mortality rate (53%).⁽¹⁾ It is potentially devastating complication of any craniofacial surgery including neurotology. It can lead to tension pneumocephalus, where a ball-valve mechanism allows air to enter but not exit the cranial vault. Therefore, pneumocephalus patients need to be investigated for the underlying causes and treated with close monitoring of any sign of increased intracranial pressure until pneumocephalus is completely resolved.

The ear has been reported as an access point for air to track into the intracranial space.⁽²⁻⁵⁾ Frequent positive pressurization has also been reported to cause pneumocephalus too^(6,7). Schrijver et al⁽⁶⁾ described a patient with a large, asymptomatic pneumocephalus caused by the frequent performance of Valsalvas' maneuver. CT scan showed epidural air collection seemingly in continuity with the left mastoid. Some authors believe that hypercellular mastoid air cells could be a risk factor for pneumocephalus, with positive pressure from forceful Valsalva sneezing and nose blowing contributing factors.⁽⁸⁻¹⁰⁾ Interestingly, pneumocephalus can be discovered incidentally with minimal symptoms. Anorbe et al⁽⁹⁾ reported pneumocephalus patient who had no symptoms except progressively enlarging retroauricular mass which increased in size on Valsalva maneuvers. Babl et al⁽⁷⁾ report a child who presented with headache and was found to have atraumatic pneumocephalus.

We propose three possible mechanisms which could explain the path of air in this pneumocephalus. Firstly, it could be

through the anterior cribiform plate, considering the diseased paranasal sinus. This is unlikely given the location of the air and the flap site of subcutaneous air. Secondly, through the cochleostomy for the cochlear implant, although we did not see any pneumocochlea in CT scan, and again it does not explain the subcutaneous air. The third proposed mechanism is through the drilled mastoid's air cells. This can be via the exit array drilling to the receiver stimulator site. Here the dura is exposed for seating the receiver stimulator, and erosion here might allow subdural air to track intracranially, possibly following a sulcus. It is also possible that it tracked along the petrous apex air cells and broke through the dura at their apex.

There have been a few reports of mastoid surgery associated with pneumocephalus.⁽¹¹⁻¹⁴⁾ This is the second case report linking this serious complication with cochlear implantation. Gillett et al⁽¹⁵⁾ reported the first case of pneumocephalus discovered within 1 week post surgery. Their patient uses to do Valsalva's manoeuvre 30 times a day to clear his ear. He recovered completely with close observation and grommet insertion. Backous et al⁽¹⁶⁾ reported two cases of flap elevation with air after cochlear implant both of them responded to conservative treatment: pressure dressing, tube insertion and antibiotic. Both patients reproduced the flap elevation with Valsalva maneuver. The interesting thing in our patient is the delayed onset as well as asymptomatic pneumocephalus which could be missed easily.

In summary, we present a rare intracranial complication of cochlear implantation, and one we have not been able to find previously reported in our review of the literature. This case is instructive, in that nasal polyposis and chronic nose blowing should be considered as potential risk factors either for soiling of the implant with contaminated nasopharyngeal secretions, or for subcutaneous or intracranial air. The authors would recommend dealing with nasal disease that might result in nose blowing or Valsalva type maneuvers prior to implantation.

References

1. Nolla SJ, Balaguer ME, Carrasco GG, Llovet TJ, Sole LJ. [Pneumoencephalos: etiology, pathologic significance and diagnosis. Apropos of 13 observations]. *Neurologia* 1989; 4(1):12-18.
2. Krayenbuhl N, Alkadhi H, Jung HH, Yonekawa Y. Spontaneous otogenic intracerebral pneumocephalus: case report and review of the literature. *Eur Arch Otorhinolaryngol* 2004.
3. Rebol J, Munda A, Tos M. Hyperpneumatization of the temporal, occipital and parietal bones. *Eur Arch Otorhinolaryngol* 2004; 261(8):445-448.
4. Bahloul K, Kalamarides M, Bouccara D, Sterkers O, Rey A. [Spontaneous otogenic pneumocephalus]. *Neurochirurgie* 2003; 49(2-3 Pt 1):110-113.
5. Vallejo LA, Gil-Carcedo LM, Borrás JM, De Campos JM. Spontaneous pneumocephalus of an otogenic origin. *Otolaryngol Head Neck Surg* 1999; 121(5):662-665.
6. Schrijver HM, Berendse HW. Pneumocephalus by Valsalva's maneuver. *Neurology* 2003; 60(2):345-346.
7. Babl FE, Arnett AM, Barnett E, Brancato JC, Kharasch SJ, Janecka IP. Atraumatic pneumocephalus: a case report and review of the literature. *Pediatr Emerg Care* 1999; 15(2):106-109.
8. Richards SD, Saeed SR, Laitt R, Ramsden RT. Hypercellularity of the mastoid as a cause of spontaneous pneumocephalus. *J Laryngol Otol* 2004; 118(6):474-476.
9. Anorbe E, Aisa P, Saenz dO. Spontaneous pneumatocele and pneumocephalus associated with mastoid hyperpneumatization. *Eur J Radiol* 2000; 36(3):158-160.
10. Maier W, Fradis M, Scheremet R. Spontaneous otogenic pneumocephalus. *Ann Otol Rhinol Laryngol* 1996; 105(4):300-302.
11. Artazkoz del Toro JJ, Faubel SM, Vendrell Marques JB, Pons RF, Campos Dana JJ. [Pneumocephalus as a complication of mastoid surgery]. *An Otorrinolaringol Ibero Am* 1993; 20(5):495-504.
12. Andrews JC, Canalis RF. Otogenic pneumocephalus. *Laryngoscope* 1986; 96(5):521-528.
13. Wortzman G, Holgate RC. Pneumocephalus following mastoid surgery: a report of two cases. *Neuroradiology* 1976; 11(2):103-105.
14. Alonso WA, Gill AJ. Pneumocephalus following mastoid surgery: a case report. *Laryngoscope* 1969; 79(12):2150-2154.
15. D GILLET, J ALMEYDA, D WHINNEY, L SAVY, JM GRAHAM. Pneumocephalus - an unreported risk of Valsalva's manoeuvre following cochlear implantation. *Cochlear Implants International* 2002;(3.1):68-74.
16. Backous DD, Pierce C, Quigley SM. Valsalva-induced scalp flap elevation after cochlear implantation: etiology and treatment 1. *Adv Otorhinolaryngol* 2000; 57:75-77.